

Differential Diagnosis for Right Axis Deviation

Tel-Hashomer – Pnimit Bet

By Baruch Goldberg

September 7, 2009

Differential Diagnosis for Right Axis Deviation

Right Ventricular Hypertrophy

ex. Pulmonary strain (Cor Pulmonale, Pulmonary A. Stenosis, PE, COPD)

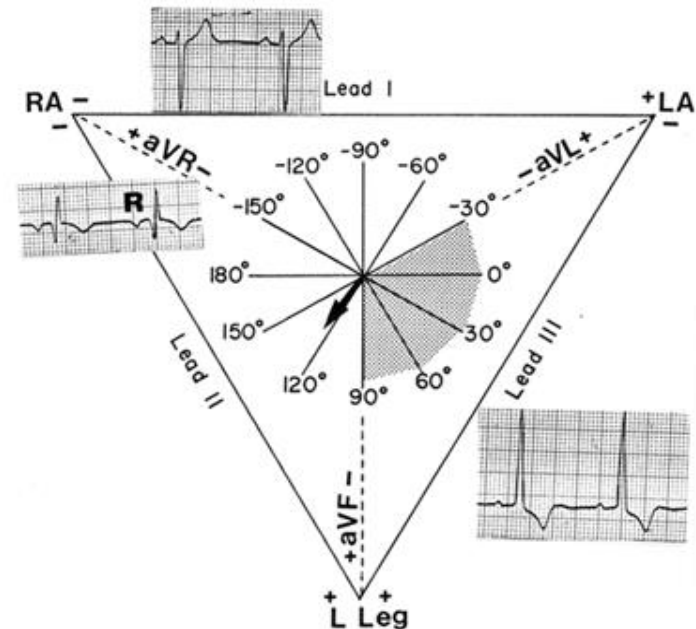
Congenital Defects (ASD, PDA, VSD)

Wolff-Parkinson-White syndrome with a left-sided accessory pathway

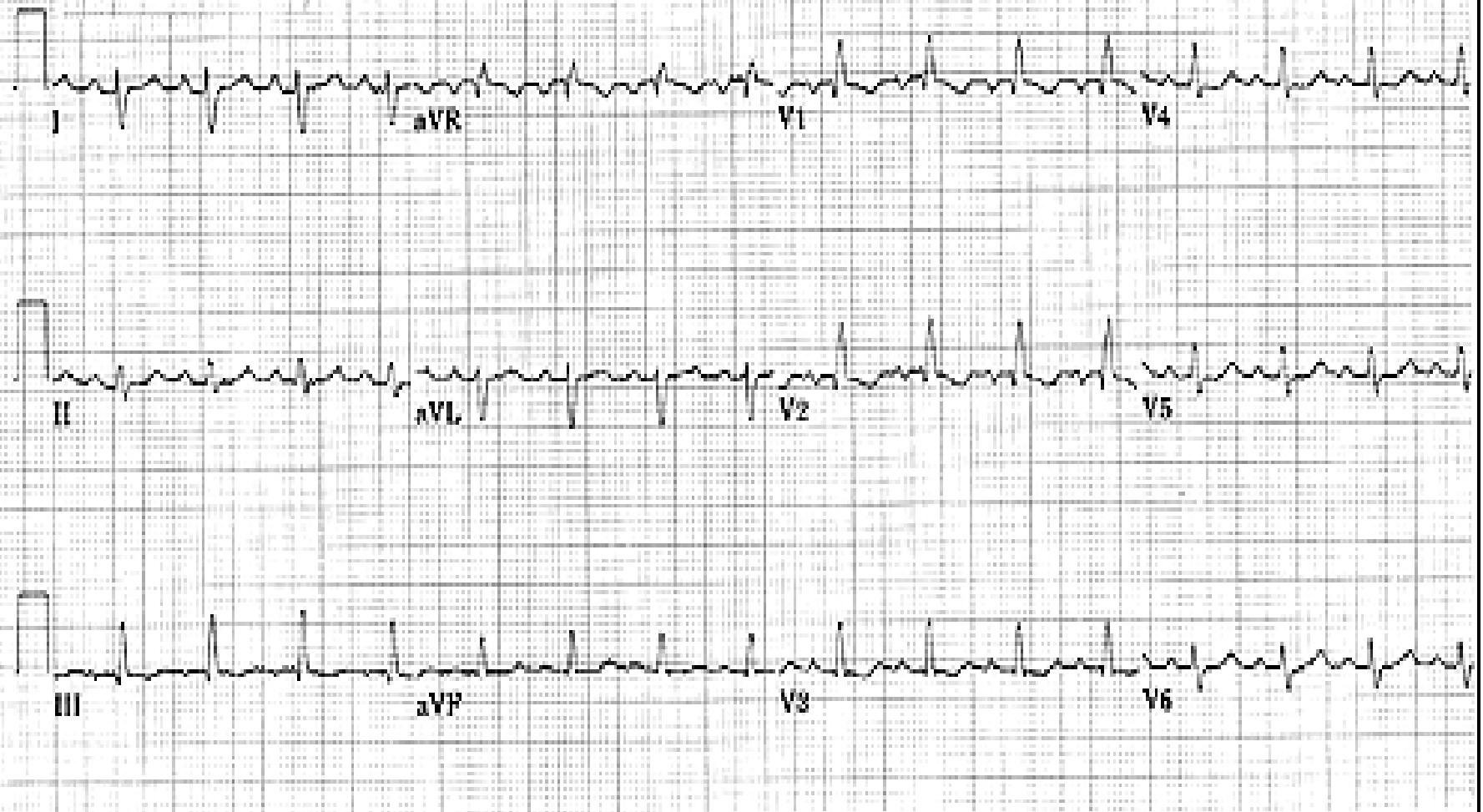Left Posterior hemiblock

Situs Inversus

* May be normal in Tall/Thin Build



19-017-1962 (44 yr)
Female Caucasian



Works Cited

- Hampton, John R. The ECG Made Easy. Nottingham, UK: Elsevier, 2008 •
- Hope, R. A. et al., eds. Oxford Handbook of Clinical Medicine. Oxford University Press, 1997. •