

ACNE, HIDRADENITIS AND ROSACEA

SHEBA MEDICAL CENTER
DERMATOLOGY DEPARTMENT

IRENE FRANTZIS
P YEAR, SGUL

OVERVIEW

- Definition
- Epidemiology
- Presentation
- Diagnosis
- Management

ACNE

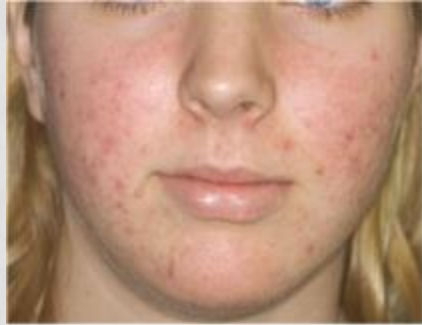- Many types (acne conglobata, acne fulminans...)
- Will focus on **acne vulgaris**
 - Skin disease affecting the pilosebaceous unit
 - Multifactorial pathogenesis
 - Genetics
 - follicular epidermal hyperproliferation with subsequent plugging of the follicle
 - Excess sebum production (androgens)
 - *Propionibacterium acnes* colonization
 - *Gram positive rods*
 - inflammation

ACNE VULGARIS

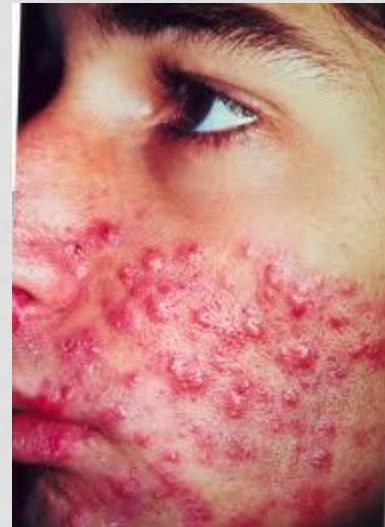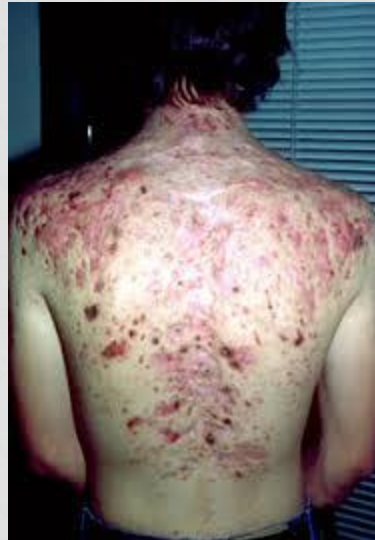- Comedones, papules, pustules, nodules, cysts, and/or scarring, primarily on the face and trunk.
- Epidemiology
 - 80% of Americans
 - Mostly adolescents (boys more as teenagers, women have more adult-form)
 - Cystic acne prevalent in Mediterranean region

ACNE VULGARIS

Mild acne



Severe acne



RISK FACTORS

- **Strong**
- age 12 to 24 years
- genetic predisposition
- greasy skin/increased sebum production
- Medications
- **Weak**
- endocrine disorders
- dietary factors
- female gender/oestrogens
- obesity/insulin resistance
- Hyperandrogenism
- halogenated aromatic hydrocarbons exposure

DIFFERENTIAL DIAGNOSIS

- Acne Conglobata
- Acne Fulminans
- Acne Keloidalis Nuchae
- Acneiform Eruptions
- Folliculitis
- Perioral Dermatitis
- Rosacea
- Sebaceous Hyperplasia
- Syringoma
- Tuberous Sclerosis

TREATMENT

- Non-hormonal related (and not pregnant)
 - Mild acne- no inflammation
 - Topical keratolytic
 - Adapalene or tretinoin or tazarotene
 - Salicylic Acid- secondary option
 - Mild acne with inflammation
 - 1st line: topical retinoids + topical antibiotics/ benzoyl peroxide
 - Topical antibiotics:
 - Clindamycin, erythromycin, dapsone
 - Can add azelaic acid (antimicrobial with mild comedolytic and anti-inflammatory properties.)

ACNE TREATMENT

- Moderate acne without inflammation: topical retinoid
- Moderate acne with inflammation
 - Topical retinoid + oral antibiotic
 - Tetracycline, doxycycline, minocycline (primary option)
 - Erythromycin (secondary option)
 - Trimethoprim/sulfamethoxazole (tertiary option)
 - Add: azaleic acid, benzoyl peroxide
- Severe/Resistant acne
 - Oral retinoid (isotretinoin)
 - Warn about side effects- headaches, decreased night vision, psychiatric effects
 - Can add oral corticosteroid

ACNE TREATMENT

- Hormone-related (but not pregnant)
 - Oral hormone therapy
 - OCP
 - Spirinolactone
 - If inflammatory, can add
 - Oral antibiotic + topical retinoid
 - Azelaic acid
 - Benzoyl peroxide
- Pregnant women
 - Topical clindamycin or topical erythromycin or azaleic acid

HIDRADENITIS SUPPURATIVA

- Chronic inflammatory dermositis
- Acneiform disorder which begins with occlusion of follicular gland
- Disorder of the terminal follicular epithelium in apocrine gland- containing skin
- Progressive
- Can cause keloids, contractures immobility

ETIOLOGY OF H.S.

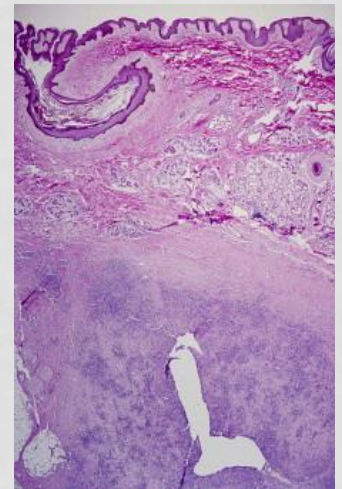
- Largely unknown
- Look at genetics
- Smoking may be triggering factor
- Associated with hirsutism, obesity, and acne in women, but still not clear
- Infection? Deodorant use?

HIDRADENITIS SUPPURATIVA

- Epidemiology:
 - Occurs in otherwise healthy individuals
 - 1-2% of general population in the USA
 - Rarely seen before puberty
- History:
 - Insidious onset
 - Pruritus, erythema, local hyperhidrosis
 - Lesions become painful
 - arthropathy

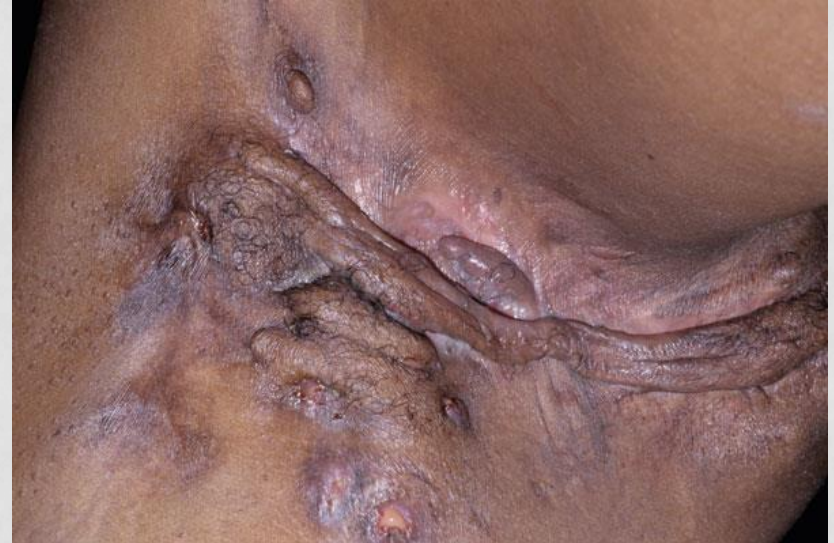HIDRADENITIS SUPPURATIVA

- Diagnosis- rarely needs biopsy
 - Need 3 elements
 1. Typical lesions
 2. Characteristic distribution
 3. Recurrence
- Histology-
 - follicular hyperkeratosis and infundibulofolliculitis.



TYPICAL LESIONS OF HIDRADENITIS

- Painful and/or tender erythematous papules smaller than 1 cm in diameter
- Painful and/or tender erythematous nodules larger than 1 cm in diameter
- Painful or tender abscesses and inflamed discharging papules or nodules
- Dermal contractures and ropelike elevation of the skin
- Double-ended comedones



HIDRADENITIS SUPPURATIVA

Characteristic Distribution

- Axillae
- Groin

Recurrence

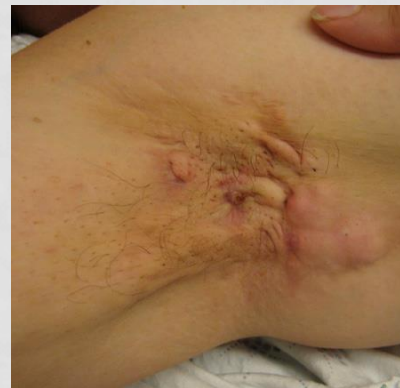- Active disease with 1 or more primary lesion in a designated site, plus a history of 3 or more discharging or painful lumps (not specified) in designated sites since age 10 years

OR

- Inactive disease with a history of 5 or more discharging or painful lumps (unspecified) in designated sites since age 10 years, in the absence of current primary lesions^[5, 6]

STAGING

- Hurley stage I (mild): presence of abscesses and inflammatory nodules but without scarring.
- Hurley stage II (moderate): presence of abscesses and inflammatory nodules with scarring. However, inflammatory lesions and scars are separated by areas of intervening normal skin.
- Hurley stage III (severe): extensive interconnected scars with or without active inflamed lesions.



MANAGEMENT

- Acute abscess:
 - Drainage
 - Antibiotics (Tetracycline or doxycycline or minocycline or amoxicillin)

MANAGEMENT

- Hurley Stage I
 - Topical antibiotics (2 x daily)
 - Topical clindamycin (1%)
 - Topical metronidazole (1%)
 - Topical chlorhexidine (4%)
 - Topical hexachlorophine (3%)
 - Oral antibiotics (adjunct)
 - Tetracycline, doxycycline, minocycline
 - NSAID
 - Pain usually correlates to degree of inflammation
 - Ibuprofen 600-800 mg

MANAGEMENT- H.S.

- Hurley Stage II
 - Oral antibiotics (1st line)
 - Doxycycline – 8 weeks
 - Clindamycin + Rifampicin- 10 wks
 - Trimethoprim/sulfamethoxazole- 8 wks
 - Topical antibiotics (1st line)
 - Dapsone +/- prednisolone (3-4 wks)
 - should improve by 12 weeks
 - Spirinolactone- if premenstrual flare. Use for 8 wks
 - Oral retinoids – if with acne vulgaris
 - Surgery- if with scarring

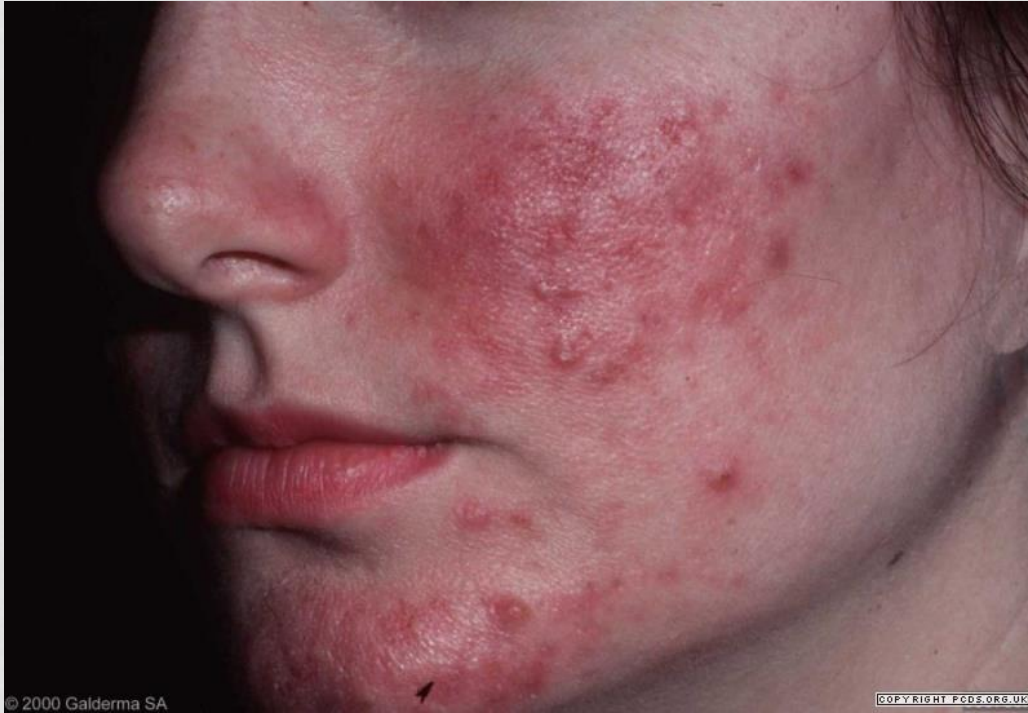MANAGEMENT H.S.

- Hurley Stage III
 - Oral antibiotics + topical antibiotics
 - Dapsone +/- prednisolone
 - NSAID
 - TNF- α inhibitor (infliximab or etanercept)
 - Spirinolactone
 - Oral retinoids
 - surgery

H.S. COMPLICATIONS

- Scarring
- Cellulitis
- Squamous cell carcinoma (low risk)
- Lymphoedema
- sepsis

ROSACEA



© 2000 Galderma SA

COPYRIGHT PCDS.ORG.UK

ROSACEA

- Chronic skin disorder
- Redness, flushing
- Telangiectasia, roughened skin, inflammation similar to acne
- Episodes of remission and recurrence
- Affects central part of face- cheeks, chin, nose
- Can affect upper trunk

ROSACEA

Epidemiology

- Affects up to 5% of US population, 10% in Europe
- 78% are unaware of condition
- Mostly fair- skinned people
- High distribution in people of Celtic origin

Etiology- Triggers

- **Climatic exposure-** solar radiation
- **Vasodilatory** response to hot showers, hot drinks
- **Chemical agents-** amiodarone, spicy foods, nasal steroids, topical steroids
- **Inflammation**

DIAGNOSIS

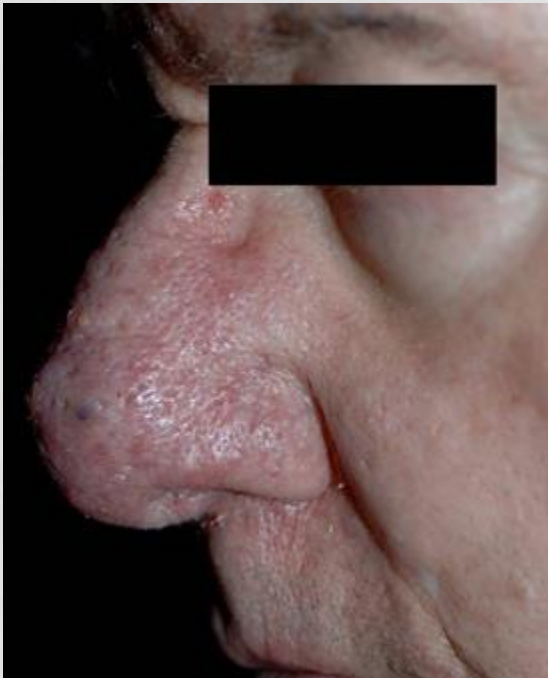- Clinical
- Histological findings are non-specific (telangiectasias, demodex mites, plasma cells present)
- Exclude differential diagnoses-
 - SLE
 - Connective Tissue disease
- Staging

ROSACEA- CLASSIFICATION

- Subtype I: ***Erythematotelangiectatic***
 - Flushing, persistent facial erythema
 - Roughness, scaling
- Subtype II: ***Papulopustular***
 - Classic type
 - Transient pustules/ papules in central facial region
 - Persistent facial erythema

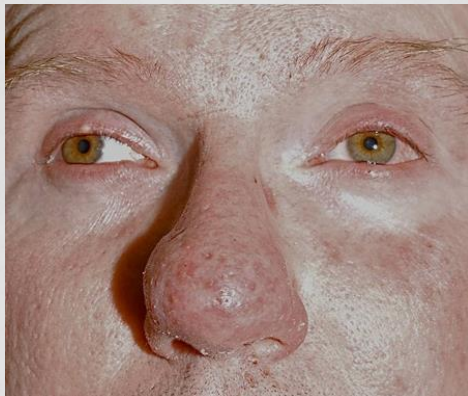CLASSIFICATION

- Subtype III: ***Phymatous***
 - Thickened skin
 - Irregular nodularities
 - Rhinophyma- also may occur in ears, eyelids



CLASSIFICATION

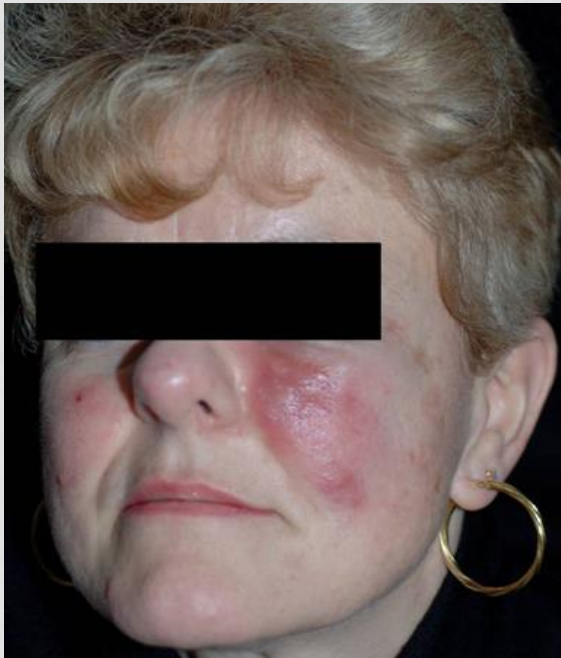- Subtype IV: ***Ocular manifestations***
 - Watery, bloodshot eyes
 - Dryness, burning, stinging
 - Foreign body sensation
 - Light sensitivity
 - Telangiectases of the conjunctiva and lid margin, or lid and peri-ocular erythema.



<http://bestpractice.bmj.com/best-practice/monograph/102/basics/classification.html>

ROSACEA FULMINANS

- “Characterised by dramatic eruption of inflamed papules and yellow pustules. ”



STAGING

- Stage 1: transient erythema (flushing)
- Stage 2: persistent erythema
- Stage 3: dome-shaped red pustules/papules over forehead, malar areas, nose, chin. Non-tender and without scarring
- Stage 4: telangiectasia

TREATMENT

- Subtype I, II, mild form subtype III
 - Initiate treatment with topical metronidazole (0.75% or 1%)
 - Topical Azelaic acid (in the US)
 - Topical sulfur
 - Doxycycline (100mg PO)
 - Tetracyclines, erythromycin if other antibiotics do not work
 - Treatment for 6-12 months, then taper off
 - Can add benzoyl peroxide
 - Laser treatment +/- tacrolimus for telangiectases and erythema

TREATMENT

- Severe subtype III
 - Invasive procedures (evidence class C)
 - Electrosurgery
 - Cryotherapy
 - Laser
 - “hot scapel” (Shaw scapel)
 - If no success- oral isotretinoin
- Subtype IV
 - Artificial tears and warm water rinses
 - Can add
 - Topical metronidazole
 - Topical ciclosporin
 - Oral tetracyclines

THANK YOU

- BMJ best practice
- Medscape reference